AIUM Practice Parameter for the Performance of Point-of-Care Ultrasound Examinations

Videos online at jultrasoundmed.org

Introduction

The clinical aspects of this parameter were developed collaboratively among the AIUM and other organizations whose members use ultrasound for performing point-of-care examinations to answer a specific clinical question (see "Acknowledgments"). Recommendations for practitioner requirements, the written request for the examination, procedure documentation, and quality control vary among the organizations and are addressed by each separately.

This practice parameter has been developed to assist practitioners performing point-of-care ultrasound examinations to evaluate the abdomen and retroperitoneum, thorax, or heart or to assess for deep vein thrombosis (DVT). For point-of-care emergency ultrasound guidance, please refer to the American College of Emergency Physicians *Emergency Ultrasound Guidelines and Imaging Compendium.* For procedure guidance, please refer to the *AIUM Practice Parameter for the Performance of Selected Ultrasound-Guided Procedures.*

A point-of-care ultrasound examination is a unique diagnostic test, which is complementary to the physical examination. Although it is not possible to detect every abnormality, adherence to the following practice parameter will maximize the probability of answering the clinical questions prompting the study. Occasionally, an additional and/or comprehensive ultrasound examination may be necessary. The use of ultrasound in a particular institution or setting must be based on access to equipment and appropriately trained personnel and should be subject to an organized quality assurance program.

Qualifications and Responsibilities of Personnel

See www.aium.org for AIUM Official Statements, including *Standards and Guidelines for the Accreditation of Ultrasound Practices* and relevant Training Guidelines.

Written Request for the Examination

A written request is not required for examinations provided at the point of care.

doi:10.1002/jum.14972

Specifications of the Examinations

A point-of-care ultrasound examination should be performed for a valid medical indication. These indications are listed for each individual section. Nevertheless, there are no absolute contraindications for the examinations included in this practice parameter.

Ultrasound may be technically limited due to bowel gas, obesity, subcutaneous emphysema, patient positioning, the degree of injury and rate of bleeding, adhesions from prior surgery, surgical dressings and tubes, and in patients who are in pain.

The main limitation of the point-of-care examination is its operator dependency. The operator must be knowledgeable in its clinical use and be appropriately trained in image acquisition and in interpretation of the findings. Spectral, color, and power Doppler imaging may be useful to differentiate vascular from nonvascular structures in any location. Measurements should be considered for any abnormal area. Limited examinations, which do not answer the clinical question, or incidental findings that warrant further investigation should prompt a comprehensive study.

Abdominal

Evaluation of the Urinary System

Indications/Contraindications

Indications for a point-of-care ultrasound examination of the urinary system include but are not limited to[1]:

- Acute kidney injury;
- Oliguria;
- Hematuria;
- Undifferentiated shock;
- Evaluation for hydronephrosis;
- Confirmation of Foley catheter placement;
- Urinary retention;
- Evaluation for renal calculi, masses, or cysts; and
- Evaluation for a perinephric abscess.

The examination of the urinary system should include long- and short-axis views of the kidneys and bladder. Decubitus, prone, or upright positioning may provide improved views of the kidneys. Limitations of the urinary system include partial visualization of the kidney. The goal of the point-of-care examination is to assess for hydronephrosis, renal calculi, an obstructed Foley catheter, a full bladder, and other bladder abnormalities.[2,3] Use of color Doppler imaging may assist in the detection of renal calculi. A comprehensive examination should be requested for further evaluation if there is uncertainty of findings seen on the point-of-care examination.

The hepatorenal and splenorenal recesses should be evaluated for the presence of fluid. An evaluation for free or loculated peritoneal fluid should include documentation of the extent and location of any fluid identified.

Both kidneys should be evaluated for size, echogenicity, and the presence of hydronephrosis (Figure 1). The kidneys should be scanned in multiple long-axis and transverse planes for a thorough evaluation. A maximal longitudinal measurement of renal length should be documented. Renal echogenicity should be compared to the adjacent liver or spleen tissue. Renal cysts and masses may be encountered, which can be of benign or malignant etiology. If a focal abnormality is identified, the examiner should refer for a comprehensive ultrasound examination. Small, isolated hypoechoic renal cysts (1 or 2 cysts, <3 cm in diameter) with thin walls, posterior acoustic enhancement, and located in the upper or lower poles typically do not require a comprehensive examination.

The urinary bladder may then be evaluated in long- and short-axis planes (Figure 2). The bladder may be evaluated for the degree of distension, luminal abnormalities, wall thickening, masses, and the correct placement of a Foley catheter. If the Foley catheter is in the normal position, the bladder should be partially collapsed around it (Figure 3). As appropriate, a postvoid residual may be quantified and reported.

Figure 1. Hydronephrosis.

Evaluation of the Hepatobiliary System

Indications/Contraindications

Indications for an ultrasound examination of the abdomen include but are not limited to:

- Abdominal pain;
- Signs or symptoms that may be referred from the abdominal regions, such as jaundice;
- Palpable abnormalities such as an abdominal mass or organomegaly;
- Abnormal laboratory values;
- Follow-up of known or suspected abnormalities in the abdomen;
- Abdominal trauma; and
- Search for the presence of free or loculated peritoneal fluid.

Figure 2. Full bladder.

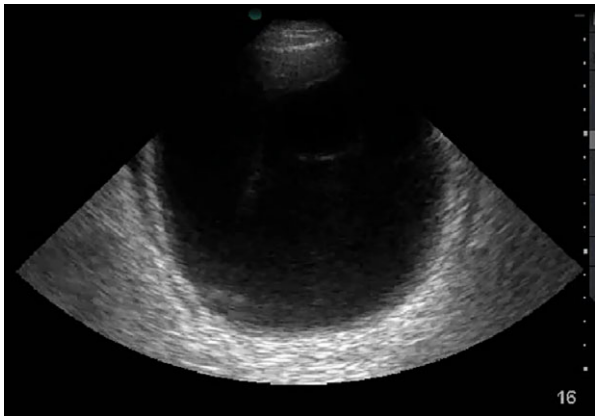

Figure 3. Obstructed Foley catheter.

The point-of-care gallbladder evaluation may include long-axis and transverse views of the gallbladder obtained in the supine position. Other positions, such as left lateral decubitus, erect, and prone, may be helpful to evaluate the gallbladder and its surrounding areas. Measurements of the anterior gallbladder wall should be considered and may aid in determining gallbladder wall thickening. If the patient presents with pain, tenderness to transducer compression should be assessed for the presence of the ultrasound Murphy sign. The presence of pericholecystic fluid should be assessed. Measurements of the anterior gallbladder wall and common bile duct should be considered. If the operator is uncertain about abnormalities found, a comprehensive right upper quadrant sonogram should be requested. Abnormalities should be correlated with symptoms and the clinical presentation.

Findings related to masses, collections, cysts, or other uncertain findings should be an indication for a comprehensive examination.

Evaluation of Free Abdominal Fluid

Indications/Contraindications

Indications for abdominal ultrasound for the evaluation of free fluid include but are not limited to:

- Evaluation for the presence, extent, and complexity of free fluid;
- Evaluation for the presence of hemoperitoneum[4,5];
- Evaluation of the trauma patient;
- Procedural guidance;
- Shock;
- Hypotension; and
- Evaluation for occult ectopic pregnancy.[6]

The examination for free fluid is usually performed in the supine position, as free fluid, unless loculated, assumes a dependent position due to a gravitational effect. Diagnosis of free fluid requires identification of anechoic or echogenic fluid in the perisplenic, hepatorenal, perihepatic, or suprapubic recess (Figure 4). Evaluation for free or loculated peritoneal fluid should include documentation of the extent and location of any fluid identified.

Evaluation for free fluid in both the hepatorenal and perisplenic recesses adjacent to the corresponding kidneys bilaterally should be performed. A thorough

evaluation of the perihepatic and perisplenic regions should also be performed.

Figure 4. Free fluid: fluid in the hepatorenal recess.

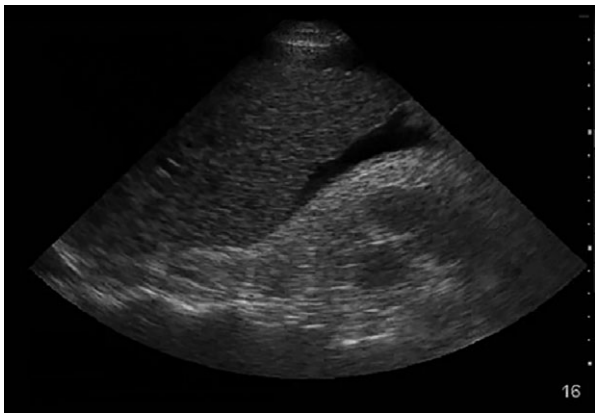

Figure 5. Abdominal aorta in the longitudinal plane with antero-posterior measurement.

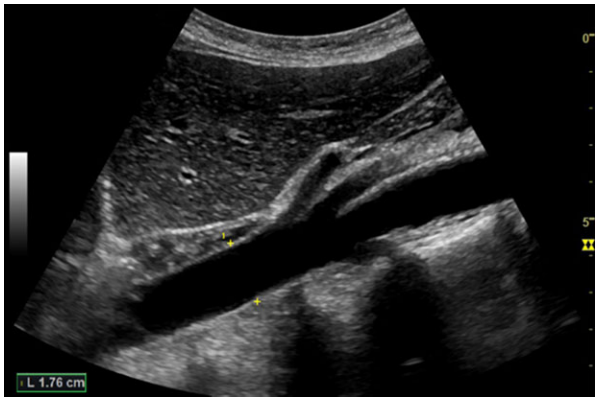

When using ultrasound to guide paracentesis, a preliminary scan is performed to identify the appropriate location of fluid and relationship with surrounding structures to determine the needle choice (length and gauge), skin entry point, needle trajectory, and tracking technique (in-plane versus out-of-plane). Doppler imaging may be used to identify regional vasculature.[7–12]

Evaluation of the Abdominal Aorta

Indications/Contraindications

Indications for an ultrasound examination of the aorta include but are not limited to:

- A palpable or pulsatile abdominal mass or abdominal bruit;
- Unexplained lower back pain, flank pain, or abdominal pain;
- An undifferentiated shock state[13–17];
- Undiagnosed acute anemia; and
- Screening for an abdominal aortic aneurysm or dissection.

The examination of the abdominal aorta may be technically limited due to body habitus, bowel gas, obesity, subcutaneous emphysema, patient positioning, the degree of injury and rate of bleeding, adhesions from prior surgery, and patients who are either in pain or combative secondary to traumatic injury. The main limitation of the abdominal examination is that the operator must be knowledgeable in its clinical use and be aware that in many patients, the entire length of the aorta may not be visualized with a point-of-care examination. If there is a high pretest

Figure 6. Abdominal aortic aneurysm in the longitudinal axis (**A**) and transverse plane (**B**) with measurements.

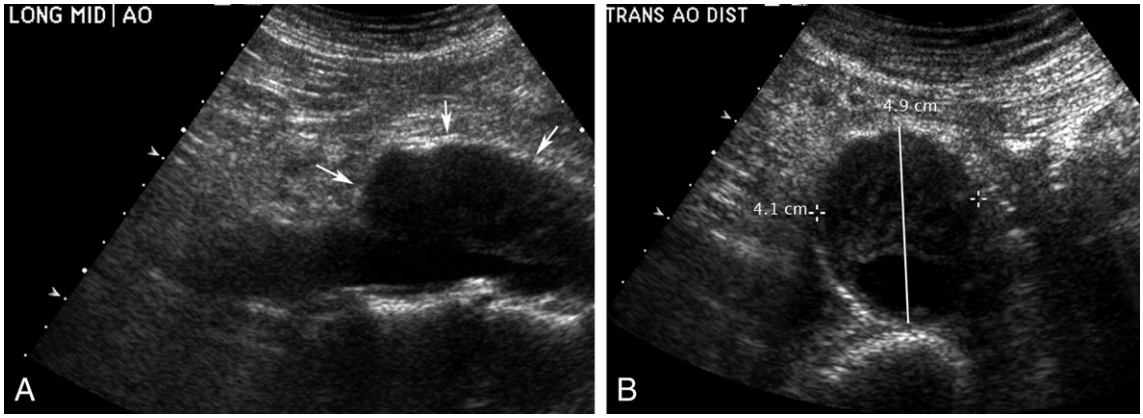

probability, further testing should be performed with computed tomography.

With the transducer in the transverse position above the umbilicus, the aorta can be found in the transverse position next to the inferior vena cava (IVC) above the spine. The abdominal aorta should be visualized in both the transverse and longitudinal planes for as much of the length of the aorta as possible (Figures 5 and 6) and should extend from the celiac axis to beyond the aortic bifurcation into common iliac arteries. Measurement of the anteroposterior dimension should be obtained by using the long- and short-axis views. Measurement of the width should be obtained in transverse or coronal views. Measurements are taken at the greatest diameter of the aorta from outer edge to outer edge. The lumen of the aorta may be examined for the presence of an intraluminal thrombus or flap. If unexpected or unexplained findings are obtained, a comprehensive examination should be ordered. However, if the patient is unstable and has an abdominal aortic aneurysm that is leaking or has ruptured, further diagnostic testing may delay timely and definitive treatment. An examination for intraluminal irregularity, a mass or narrowing, or an extraluminal mass or collection should also be performed and if found should prompt a comprehensive examination.

If an aneurysm is present, the maximal size and location of the aneurysm should be documented and recorded. The relationship of the dilated segment with the renal arteries and the aortic bifurcation should be determined if possible. Fluid or a mass adjacent to the aorta should be documented and reported. A comprehensive study may be requested to follow-up abnormal measurements.

Cardiac

Indications/Contraindications

Indications for a point-of-care ultrasound examination of the heart include but are not limited to:

- Undifferentiated shock[18–21];
- Evaluation of the pericardial space;
- Evaluation of left ventricular (LV) and right ventricular (RV) size and function;
- Determination of volume responsiveness;
- Evaluation for severe valvular dysfunction[22,23];
- Cardiopulmonary symptoms;
- Determining presence of left atrial enlargement; and
- Screening for hypertrophic cardiomyopathy in youth athletes.[24]

Limitations of the point-of-care ultrasound examination of the heart include body habitus, thoracic dressings, and subcutaneous emphysema. In addition, off-axis views may produce false-positive or false-negative results. Effort should be taken to ensure the axis is correct before interpretation of the study. Limitations to the pericardial assessment for hemopericardium include pericardial fat pads, cysts, and preexisting pericardial fluid. If the operator is uncertain of findings, a comprehensive cardiac echocardiogram should be ordered.

Point-of-Care Cardiac Examination: 5-View Approach

Scanning Technique

The heart should be evaluated by using appropriate grayscale and Doppler techniques and proper patient positioning. Adjustment of the depth and gain should be set for optimal visualization of the cardiac structures. The 5 basic views are the parasternal long-axis view, parasternal short-axis view, apical 4-chamber view, subcostal 4-chamber view, and subcostal IVC view (Views 1–5).[25–27] Not every view will be obtained, depending on the clinical question. *Comment*: Please notice that traditionally, the marker is on the right side of the monitor (opposite that of abdominal pelvic imaging).

View 1. *Parasternal long-axis view.* In this view, the marker on the transducer is pointed toward the patient's right shoulder. The transducer is placed in the 2–3 intercostal space adjacent to the sternum on the left side. An on-axis examination has both the mitral and aortic valves in view with the left ventricle (LV) in the long axis. The point-of-care information obtained from this view is assessment of LV function, left atrium size, mitral and aortic valve evaluation, evaluation for pericardial effusion, right ventricular (RV) enlargement, septal bowing, and measurement of the aortic root.

Different subspecialties place the marker on different sides of the screen. There is not one "correct" way to position the marker or the indicator on the transducer. This section suggests one method. Consistency is key, and double-checking the orientation before interpretation of images is essential.

View 2. *Parasternal short-axis view.* In this view, the marker on the transducer is pointed toward the patient's left shoulder. The papillary muscles should be in view. An on-axis view shows a cross section of the LV. This view is primarily for evaluation of LV function (ie, fractional shortening) and segmental wall motion abnormalities. It is also used to evaluate septal motion and for right ventricle (RV) enlargement causing displacement of the septum.

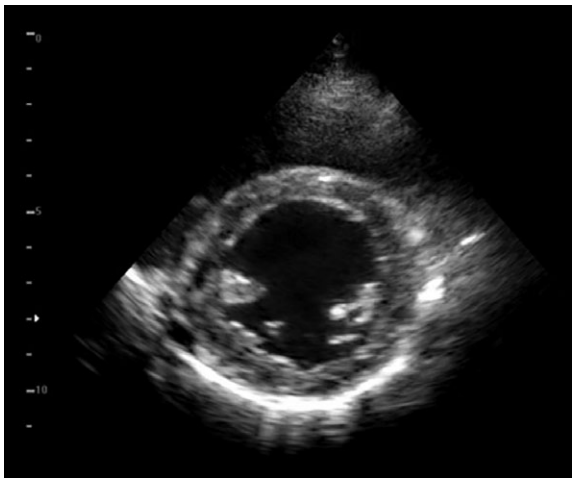

View 3. *Apical 4-chamber view.* The marker on the transducer is pointed toward the patient's left side. An on-axis view shows all 4 chambers with both the mitral and tricuspid valves in view. It is primarily used to compare RV to LV size. It is also used to evaluate LV function and to evaluate the mitral and tricuspid valves. This view can also be used to assess for pericardial effusion.

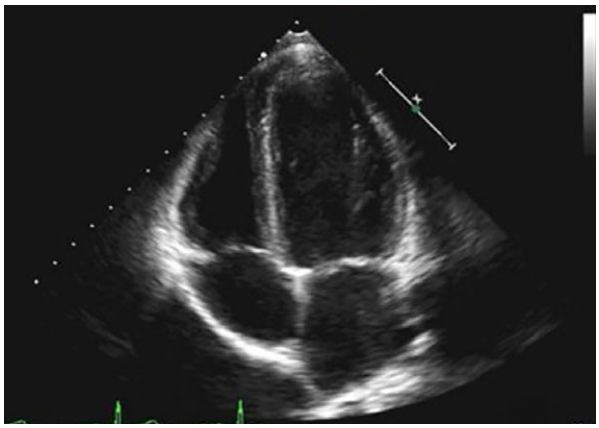

There are many other views used in advanced echocardiography that are not described here. The point-of-care examination cannot and should not replace a full cardiac echocardiogram. Limited studies that do not address the clinical question or need for further information should be an indication for a full cardiac echocardiogram.

View 4. *Subcostal 4-chamber view.* The marker on the transducer is pointed toward the patient's left side. The transducer is placed in the subxyphoid position with all 4 chambers in view. This is often the only view obtainable in hyperinflated or ventilated patients. It is used to compare RV to LV size. A pericardial effusion can also be seen in this view.

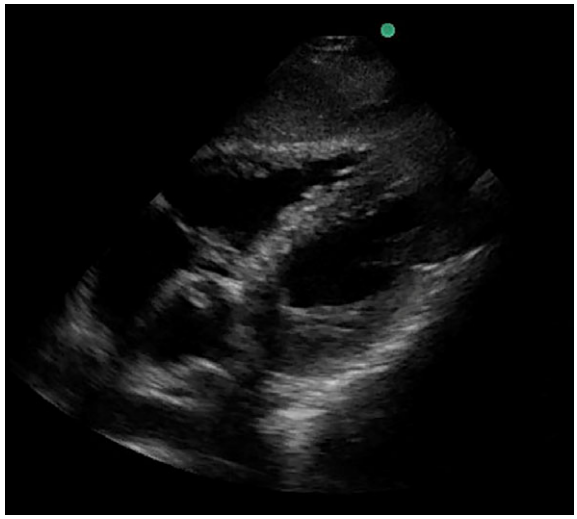

View 5. *Subcostal IVC view.* The marker on the transducer is pointed up toward the patient's head. The IVC should be seen in the longitudinal axis joining the right atrium. This view is used to look at the IVC diameter and variability as well as pericardial effusions around the right atrium. The IVC is used for volume assessment.

Deep Vein Thrombosis

Indications/Contraindications

Indications for an ultrasound examination of the lower extremity include but are not limited to[28]:

- Swollen lower extremity or extremities;
- Pain or erythema in lower extremities;
- Unexplained hypoxemia;
- Unexplained dyspnea; and
- Suspected pulmonary embolus.

Limitations of the point-of-care examination of the lower extremity are body habitus and the inability to identify key anatomic points. Any uncertainty in the examination should prompt a full lower extremity Doppler examination.

Specifications of the Examination

Compression Technique of the Lower Extremity

Note: The words *proximal* and *distal* refer to the relative distance from the attached end of the limb, per *Gray's Anatomy*. For example, the proximal femoral vein is closer to the hip, and the distal femoral vein is closer to the knee. The longitudinal or long axis is parallel to or along the length of the vein. The transverse or short axis is perpendicular to the long axis of the vein. Compression can be documented by using

Figure 7. Example of a thrombus (split-screen image).

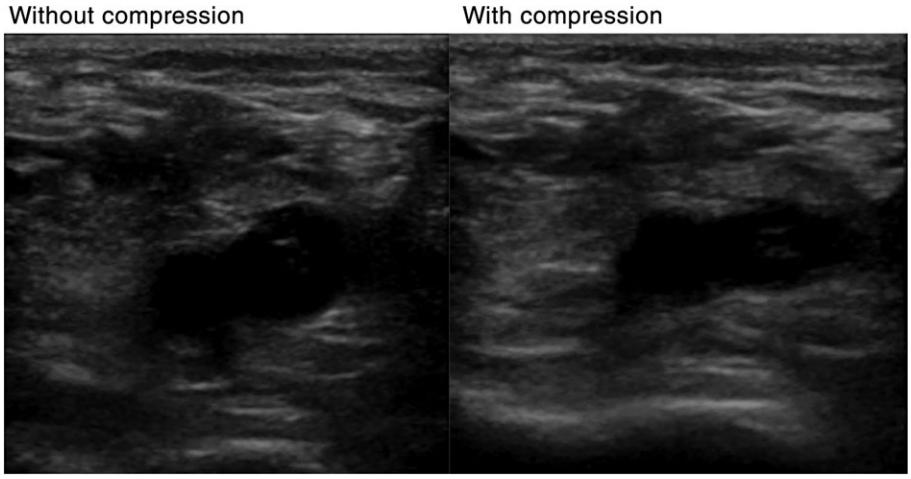

Figure 8. Example of color (split-screen image).

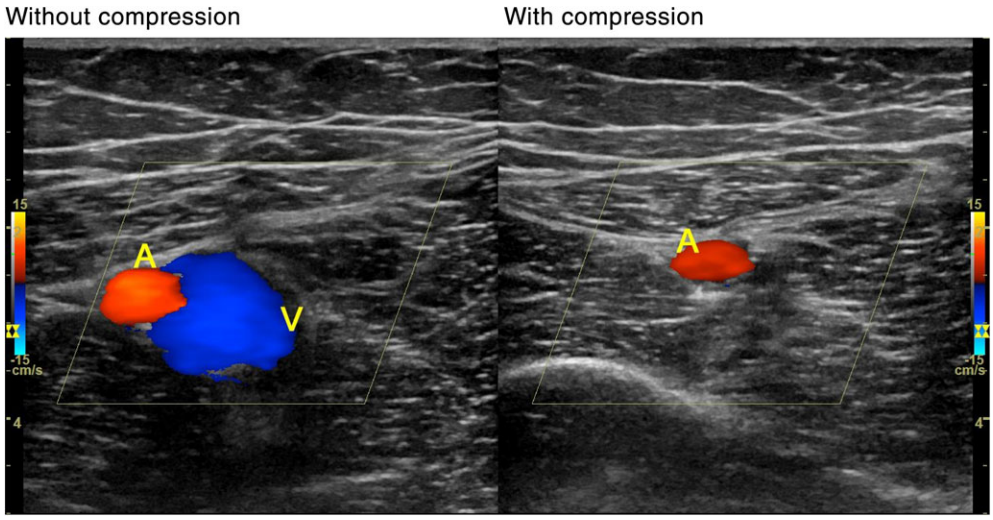

cine clips. Alternatively, images without and with compression can be used for documentation.

To assess for compressibility, perpendicular force is applied such that the anterior and posterior walls of the vein meet. Venous compression is applied every 2 cm or less in the transverse (short-axis) plane with adequate pressure on the skin to completely obliterate the normal vein lumen.[28] A positive sign for DVT is the visualization of echogenic material or a thrombus within the lumen of the vein and/or noncompressibility of that segment of the vein (Figure 7).[29–40] A color or spectral Doppler evaluation, with or without augmentation, may be used to support the presence or absence of an abnormality (Figures 8–10).

Recording the Examination

Compression ultrasound[29]: The fullest visualized extent of the great saphenous vein, saphenofemoral junction, and common femoral, femoral (formerly known as the superficial femoral), and popliteal veins[30,31] must be imaged by using an optimal grayscale compression technique (Views 6–11). The popliteal vein is examined distally to the tibioperoneal trunk.[32]

Grayscale images (or cine loops) should be recorded without and with compression at each of the following levels, at a minimum.[33–38]

Abnormal symptoms or findings may require a comprehensive study to document the complete extent of the abnormalities. Symptomatic areas such as the calf generally require an additional evaluation and additional images if the cause of the symptoms is not readily elucidated by the standard examination. The extent and location of sites where the veins fail to compress completely should be clearly recorded. Long-axis views without compression may be helpful to characterize the abnormal vein.[39–42]

Depending on the patient's presentation and clinical indication, clinical management pathways may require a more detailed comprehensive evaluation of the deep and superficial venous system, evaluation of

Figure 10. Example of a spectral Doppler image.

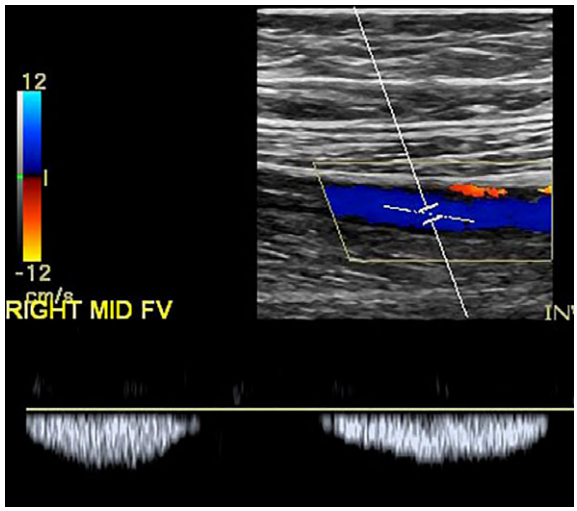

Figure 9. Example of a spectral Doppler image with augmentation.

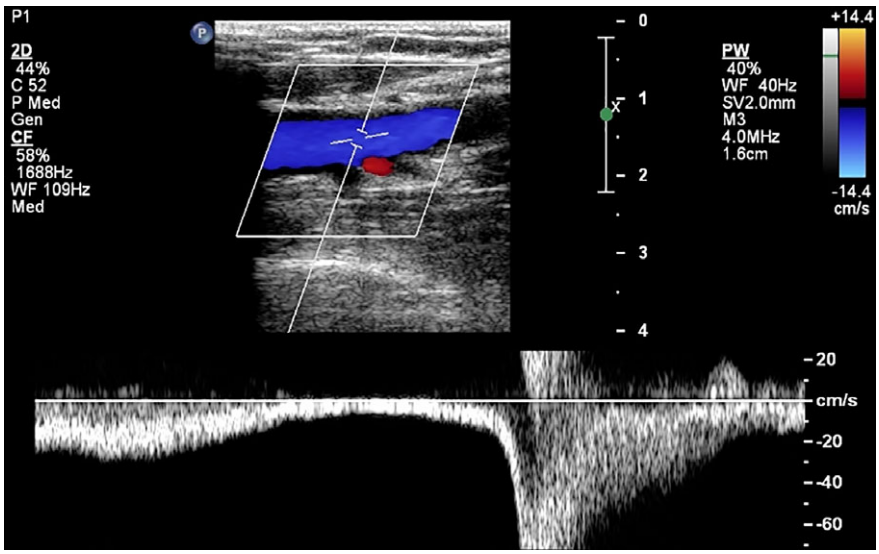

the deep calf veins, or a bilateral study.[43–48] Other vascular and nonvascular abnormalities, if found, should be recorded and may require an additional comprehensive venous examination for diagnosis.[49]

Thoracic

Scanning Technique

The thorax should be scanned by using a linear or curvilinear transducer with harmonics, compression, and smoothing turned off on the machine. A linear transducer may be used to evaluate the pleura in adults or the entire thorax in a pediatric patient. The standard transducer orientation is in the longitudinal plane with the indicator pointing to the head or patient's right. The optimum depth and gain should be set to evaluate the lung and/or pleural line. Lung setting should be selected to maximize artifacts. Turning off advanced filters such as tissue harmonics allows the artifacts from the lung to be highlighted with ultrasound. Each hemithorax should be examined in several rib interspaces in the anterior thorax at the midclavicular line, the lateral thorax in the midaxillary line, and the posterior thorax.

View 6. Common femoral vein (split-screen image).

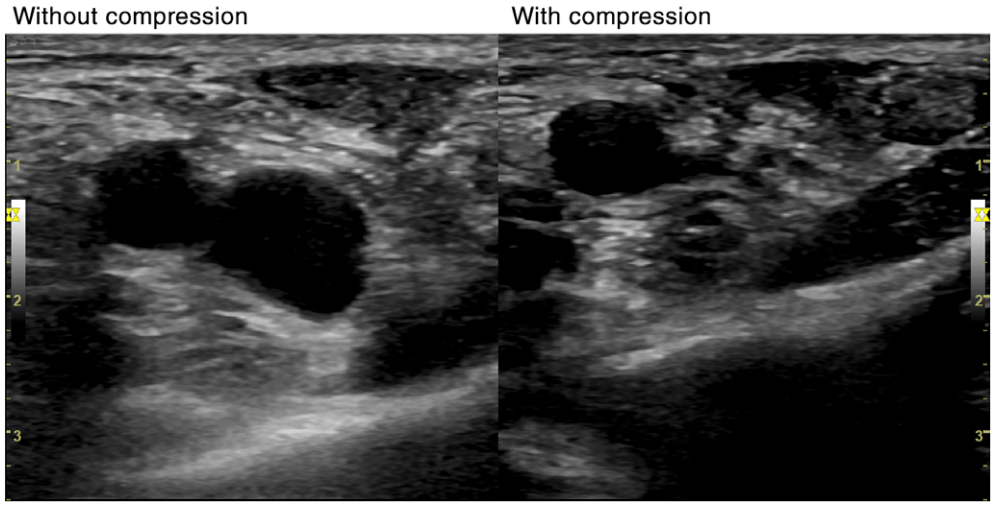

View 7. Junction of the common femoral vein with the great saphenous vein (split-screen image).

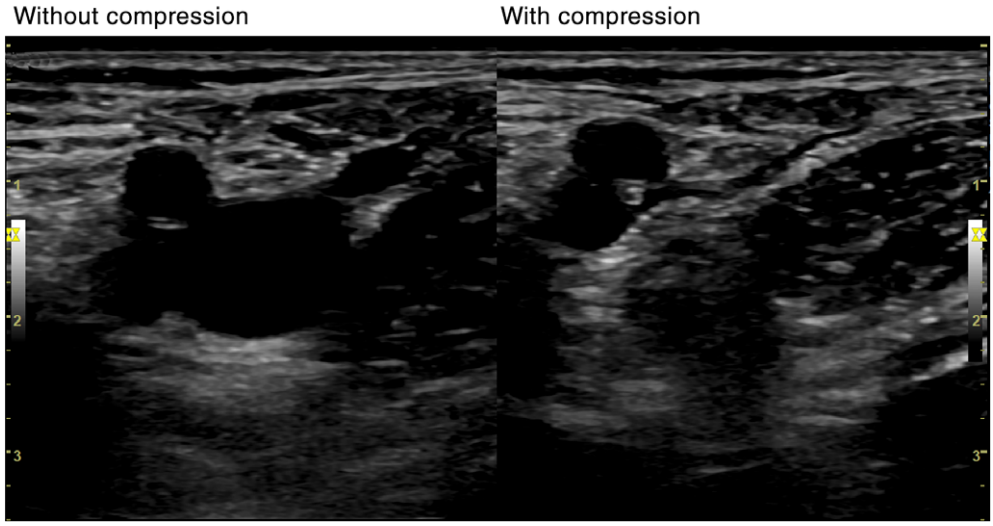

Lung Ultrasound

Indications for an ultrasound examination of the lung include but are not limited to[50]:

- Dyspnea;
- Respiratory failure;
- Undifferentiated shock;
- Suspicion of pneumothorax;
- Assessment of the volume status;
- Assessment for pleural effusions;
- Evaluation for the presence of alveolar consolidation;
- Diaphragmatic function;
- Abnormal blood gases or other laboratory findings consistent with lung pathology;
- Thoracic trauma (focused assessment with sonography for trauma);
- Pleural-based masses; and
- Planning or guidance for an invasive thoracic procedure.

View 8. Proximal deep femoral vein separately or along with the proximal femoral vein (split-screen image).

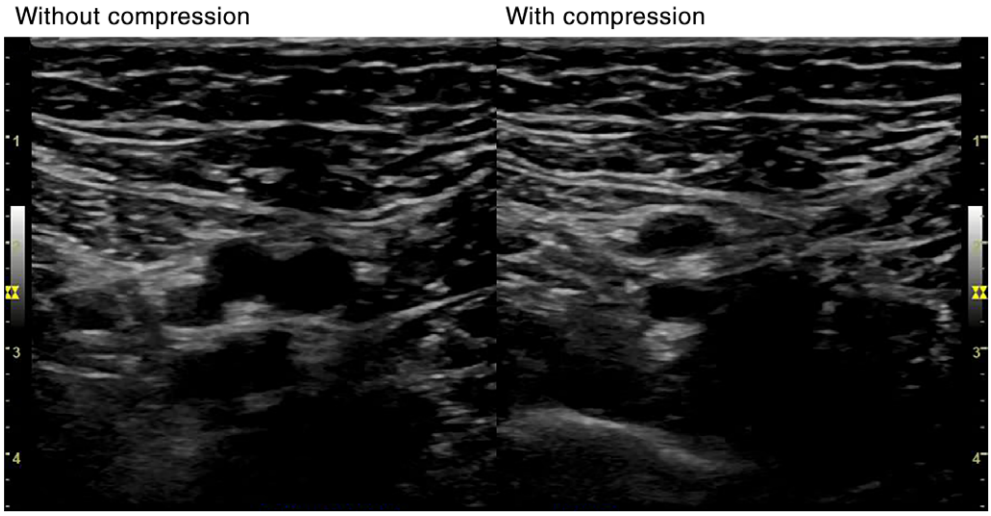

View 9. Proximal femoral vein (split-screen image).

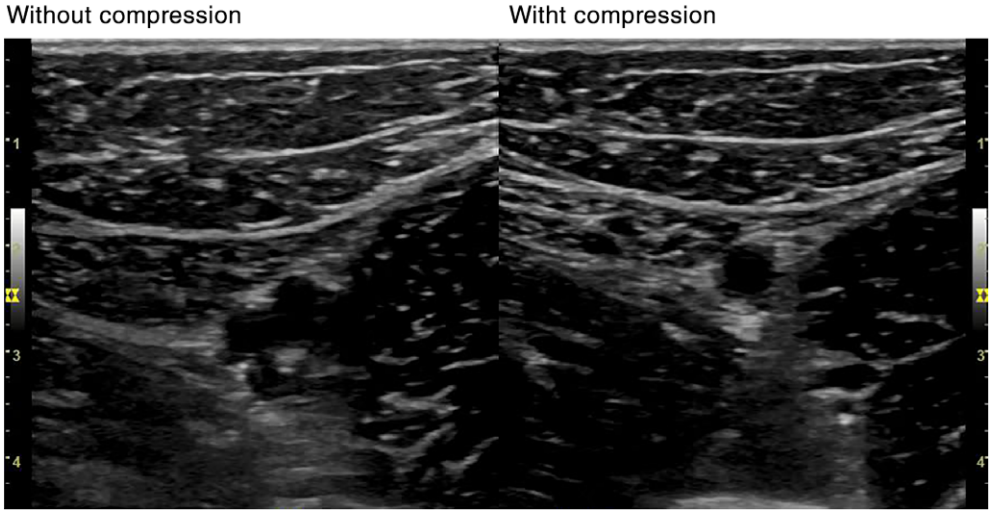

Ultrasound may be technically limited in the trauma patient because of obesity, subcutaneous emphysema, patient positioning, the degree of injury, adhesions from prior surgery, and often patients who are either in pain or combative. The main limitation of the point-of-care thoracic examination is that the operator must be knowledgeable in its clinical use.

Limitations of a point-of-care thoracic examination in the evaluation for pneumothorax include main-stem bronchus intubation, failure to recognize the lung pulse (subtle cardiac pulsation of the parietal pleura at the lung periphery) as cardiac-induced movement, patients after pleurodesis, and patients with severe chronic obstructive pulmonary disease or other lung pathology inhibiting adequate visualization of lung sliding. Although the sensitivity in the detection of pneumothorax is very high, it is important to note that small apical or localized pneumothoraces may not be visualized even in a focused thoracic ultrasound examination.

Limitations in the evaluation of the B-line pattern include the ability to differentiate between cardiogenic and noncardiogenic pulmonary edema producing a similar appearance. Limitations in the evaluation of a

View 10. Distal femoral vein (split-screen image).

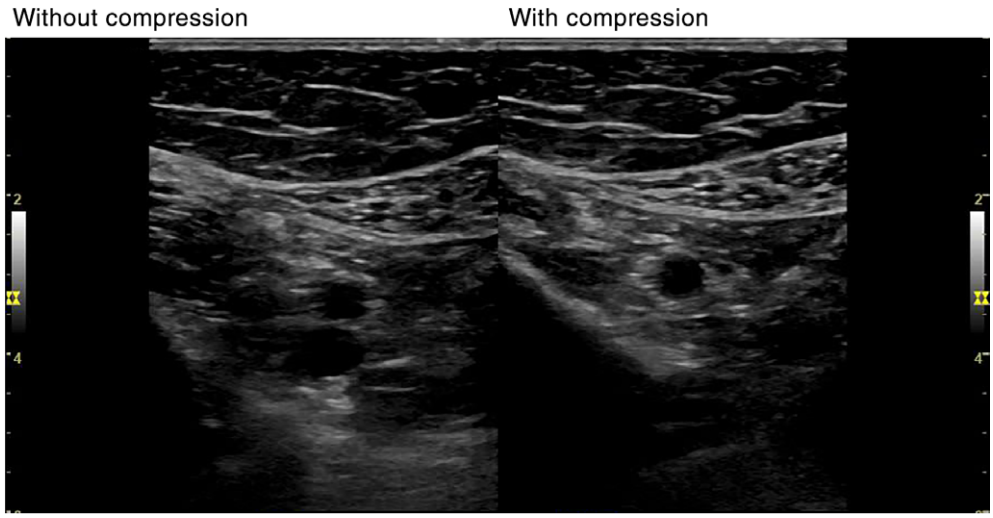

View 11. Popliteal vein (split-screen image).

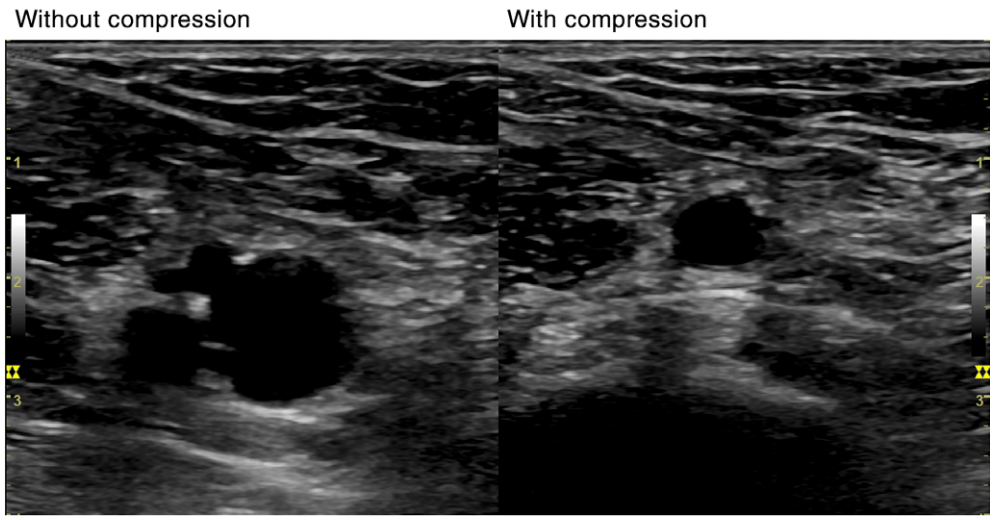

consolidation pattern include body habitus and failure to place the transducer in the posterior thorax to detect a posteriorly located consolidation.

Examples (Figures 11–15):

The finding of lung sliding is 100% sensitive for the exclusion of pneumothorax present at a given interspace. Multiple rib interfaces should be examined if the suspicion of pneumothorax is high. A small apical pneumothorax may be missed because of shadowing from bone. If the presence of lung sliding is unclear in a patient with a high pretest probability, a further evaluation should be performed.[51,52]

When this pattern is present, pneumothorax cannot be ruled out. Examples of disease processes that cause loss of lung sliding without pneumothorax include pleurodesis, severe emphysema with bullous lung disease, a severe acute respiratory distress syndrome pattern, opposing main-stem intubation, and apnea.[51–53]

A B-line pattern can be present in, but not specific to, cardiogenic and noncardiogenic pulmonary edema. The thickness of the pleura and the location of the B-line pattern may aid in the differentiation of these two disease processes.[54–58]

The clinician may be able to differentiate between atelectasis and pneumonia causing the consolidation

Figure 11. A-line pattern with lung sliding.

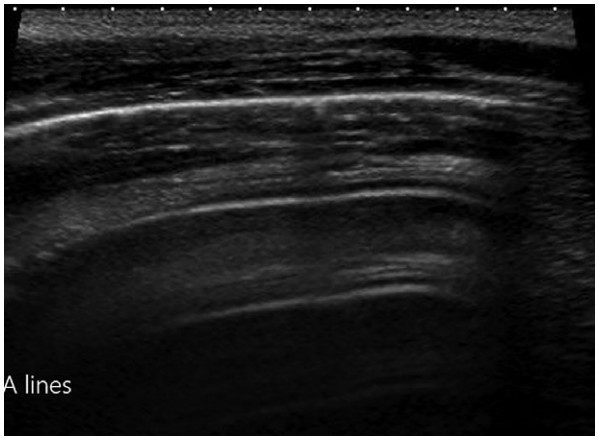

Figure 12. *A-lines* with no lung sliding.

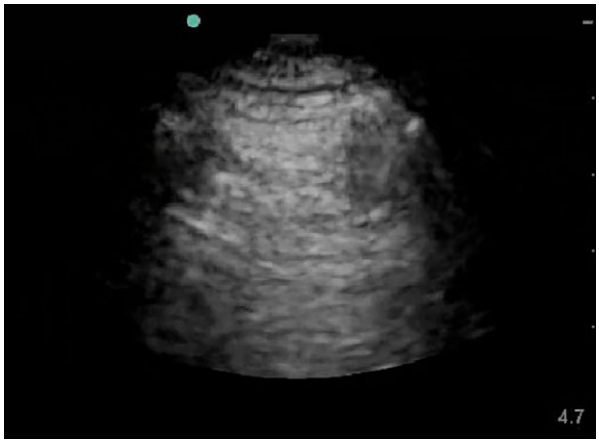

Figure 13. B-line pattern.

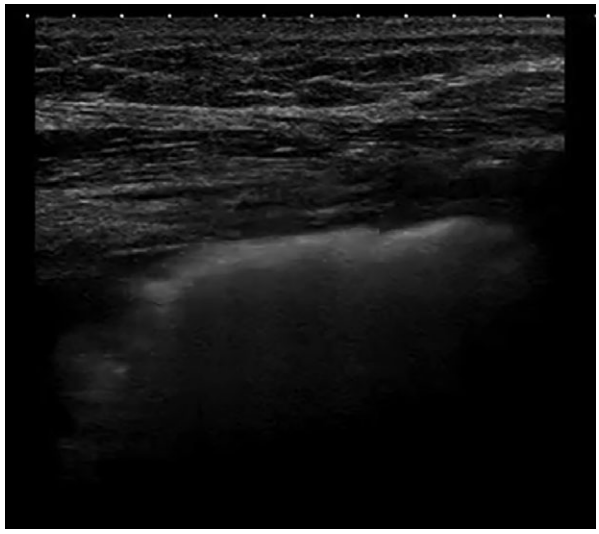

Figure 14. Consolidation pattern.

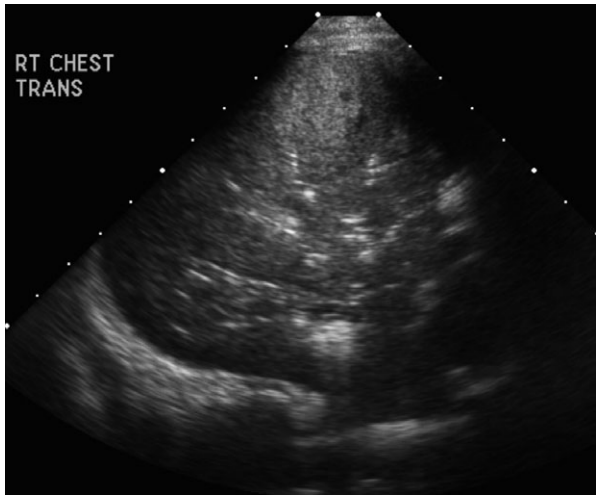

process. This is a clinical distinction, but the presence of mobile/dynamic air bronchograms indicates a bronchus that is patent.[59]

Pleural Ultrasound

Indications for pleural ultrasound include but are not limited to:

- Dyspnea;
- Evaluation for the presence, size, and complexity of pleural effusions;
- Evaluation for the presence of hemothorax;
- Evaluation of the thickness and irregularity of the pleural line;
- Suspicion of interstitial lung disease;
- Evaluation of pneumothorax; and
- Determination of the lung point.

Figure 15. Mobile air bronchograms.

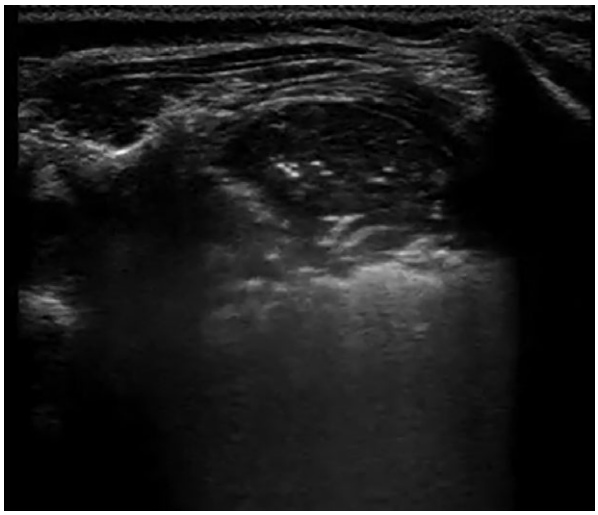

Diagnosis of a pleural effusion (View 12) requires identification of anechoic or echogenic fluid with typical anatomic boundaries (chest wall, lung surface, and diaphragm) with associated dynamic findings (eg, lung flapping, plankton sign, and diaphragmatic movement). In the supine patient, using a coronal view in the posterior axillary line, the spine sign should be sought to ensure that the anechoic region above the diaphragm is not erroneously present due to refraction artifacts. The pleural line should be examined for thickness, irregularity, and lung sliding in multiple rib interspaces.[51–57,59,60] Quantification or estimation of pleural effusion may be performed by using the methods of Balik et al[61] or Remerand et al.[62]

Pleural effusions may be examined for size, complexity, and accessibility. The complexity of the fluid in hemothorax (Figure 16) depends on the age of the collection.[51]

View 12. Pleural effusion.

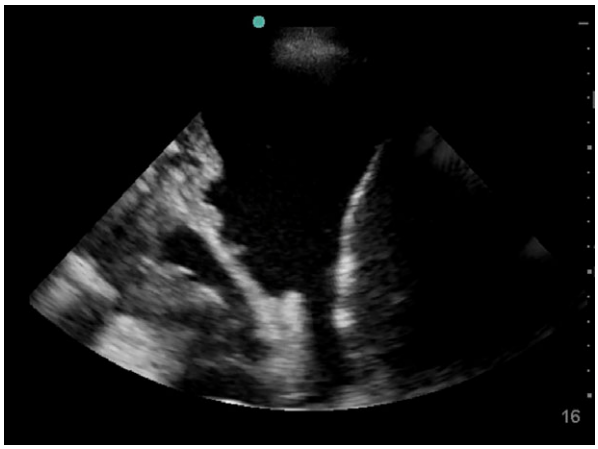

Documentation

Adequate documentation is essential for high-quality patient care. Ultrasound images that contain diagnostic

Figure 16. Hemothorax.

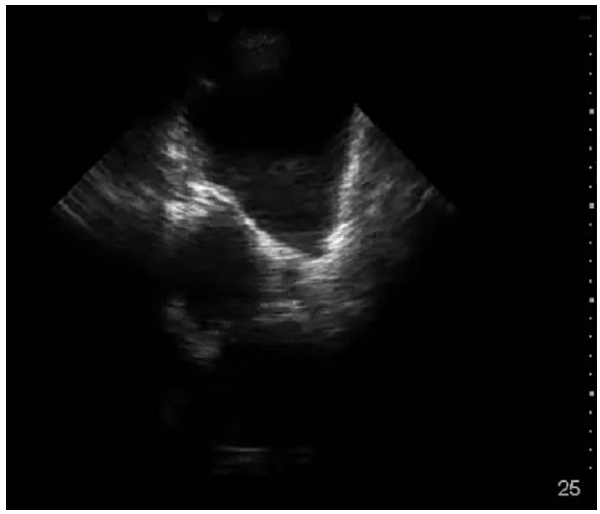

information and/or direct patient management (both normal and abnormal) should be recorded in accordance with the *AIUM Practice Parameter for Documentation of an Ultrasound Examination.*

Equipment Specifications

All studies should be performed at the point of care.

- For abdominal studies, phased array or curvilinear transducers are preferred; however, a higher-frequency linear transducer may be used. For adults, mean frequencies between 2 and 5 MHz are most commonly used. For most preadolescent pediatric patients, mean frequencies of 5 MHz or greater are preferred, and in neonates and small infants, a higher-frequency linear transducer is often necessary.
- For cardiac studies, phased array transducers are preferred. For pediatrics and adults, mean frequencies between 2 and 5 MHz are most commonly used.
- For DVT studies, equipment must be capable of real-time imaging for compression of the veins. In most cases, a linear or curvilinear transducer is preferable, but phased array scanners can be helpful for difficult patients. Transducers should transmit at a frequency of 5 MHz or greater, with the occasional need for a lower-frequency transducer. Color Doppler imaging and Doppler flow analysis can be used to augment the examination.
- For thoracic studies, phased array, curvilinear, and higher-frequency linear transducers are preferable; all may be used, with the preference varying based on the clinical question to be answered. For adults, mean frequencies between 2 and 5 MHz are most commonly used.

The equipment should be adjusted to operate at the highest clinically appropriate frequency, realizing that there is a trade-off between resolution and beam penetration. When Doppler studies are performed, the Doppler frequency may differ from the imaging frequency. Image quality should be optimized while keeping total ultrasound exposure as low as reasonably achievable (ALARA).

Quality Control and Improvement, Safety, Infection Control, and Patient Education

Policies and procedures related to quality control, patient education, infection control, and safety, including equipment performance monitoring, should be developed and implemented in accordance with the AIUM Standards and Guidelines for the Accreditation of Ultrasound Practices.

ALARA Principle

The potential benefits and risks of each examination should be considered. The ALARA principle should be observed when adjusting controls that affect the acoustic output and by considering transducer dwell times. Further details on ALARA may be found in the AIUM publication *Medical Ultrasound Safety,* Third Edition.

Acknowledgments

This parameter was developed by the American Institute of Ultrasound in Medicine (AIUM) in collaboration with Northwell Health, the American College of Chest Physicians (ACCP), the Society of Critical Care Medicine (SCCM), the Society of Hospital Medicine (SHM), and the Society of Point of Care Ultrasound (SPOCUS).

Collaborative Committee
Members represent their societies in the drafting of this parameter.

AIUM: John Pellerito, MD, cochair
Northwell: Seth Koenig, MD, cochair
ACCP: Mangala Narasimhan, MD, cochair
AIUM: Chad Jackson, MD
Paul Bornemann, MD
SCCM: Jose L. Diaz-Gomez, MD
SHM: Benji Mathews, MD
SPOCUS: Francisco Norman, MPAS, PA-C
Jonathan Monti, PA-C

AIUM Clinical Standards Committee
John Pellerito, MD, chair
Bryann Bromley, MD, vice chair
Rachel Liu, MD

Marsha Neumyer, BS, RVT
Khaled Sakhel, MD

AIUM Expert Advisory Group
Alyssa Abo, MD
Srikar Adhikari, MD, MS
David Bahner, MD, RDMS
Paul Dallas, MD
Eitan Dickman, MD
Renee Dversdal, MD
Mederic M. Hall, MD
Irene W. Y. Ma, MD, PhD
Arun Nagdev, MD
Vivek Tayal, MD

References

Abdominal

1. Mayo PH, Beaulieu Y, Doelken P, et al. American College of Chest Physicians/La Société de Réanimation de Langue Française statement on competence in critical care ultrasonography. *Chest* 2009; 135:1050–1060.
2. Noble VE, Nelson BP. *Manual of Emergency and Critical Care Ultrasound*. Cambridge; England: Cambridge University Press, 2011.
3. Smith-Bindman R, Aubin C, Bailitz J, et al. Ultrasonography versus computed tomography for suspected nephrolithiasis. *N Engl J Med* 2014; 37:1100–1110.
4. Perera P, Mailhot T, Riley D, Mandavia D. The RUSH exam: rapid ultrasound in shock in the evaluation of the critically ill. *Emerg Med Clin North Am* 2010; 28:29–56.
5. Brochard L, Abroug F, Brenner M, et al. An official ATS/ERS/ESICM/SCCM/SRLF statement: prevention and management of acute renal failure in the ICU patient—an international consensus conference in intensive care medicine. *Am J Respir Crit Care Med* 2010; 181:1128–1155.
6. Moore C, Todd WM, O'Brien E, Lin H. Free fluid in Morison's pouch on bedside ultrasound predicts need for operative intervention in suspected ectopic pregnancy. *Acad Emerg Med* 2007; 14: 755–758.
7. Mercaldi CJ, Lanes SF. Ultrasound guidance decreases complications and improves the cost of care among patients undergoing thoracentesis and paracentesis. *Chest* 2013; 143: 532–538.
8. Orman ES, Hayashi PH, Bataller R, Barritt AS IV. Paracentesis is associated with reduced mortality in patients hospitalized with cirrhosis and ascites. *Clin Gastroenterol Hepatol* 2014; 12:496–503.e1.
9. Webster ST, Brown KL, Lucey MR, Nostrant TT. Hemorrhagic complications of large volume abdominal paracentesis. *Am J Gastroenterol* 1996; 91:366–368.
10. Arnold C, Haag K, Blum HE, Rössle M. Acute hemoperitoneum after large-volume paracentesis. *Gastroenterology* 1997; 113:978–982.
11. Sekiguchi H, Suzuki J, Daniels CE. Making paracentesis safer: a proposal for the use of bedside abdominal and vascular ultrasonography to prevent a fatal complication. *Chest* 2013; 143:1136–1139.
12. Ennis JB, Schultz GR, Phillips P, Williams S, Gharahbaghian L, Mandavia DP. Ultrasound for detection of ascites and for guidance of the paracentesis procedure: technique and review of the literature. *Int J Clin Med* 2014; 5:1277–1293.
13. England S. Ultrasound assessment of the abdominal aorta. In: *Ultrasound in Emergency Care*. Hoboken, NJ: Blackwell Publishing; 2008:42–46.
14. Pellerito JS, Polak JF. *Introduction to Vascular Ultrasonography*. New York, NY: Elsevier Health Sciences; 2012:450–465.
15. Volpicelli G, Lamorte A, Tullio M, et al. Point-of-care multiorgan ultrasonography for the evaluation of undifferentiated hypotension in the emergency department. *Intensive Care Med* 2013; 39: 1290–1298.
16. Rubano E, Mehta N, Caputo W, Paladino L, Sinert R. Systematic review: emergency department bedside ultrasonography for diagnosing suspected abdominal aortic aneurysm. *Acad Emerg Med* 2013; 20:128–138.
17. Chiu KWH, Ling L, Tripathi V, Ahmed M, Shrivastava V. Ultrasound measurement for abdominal aortic aneurysm screening: a direct comparison of the three leading methods. *Eur J Vasc Endovasc Surg* 2014; 47:367–373.

Cardiac

18. Mayo PH, Beaulieu Y, Doelken P, et al. American College of Chest Physicians/La Société de Réanimation de Langue Française statement on competence in critical care ultrasonography. *Chest* 2009; 135:1050–1060.
19. Noble VE, Nelson BP. *Manual of Emergency and Critical Care Ultrasound*. Cambridge, England: Cambridge University Press; 2011.
20. Volpicelli G, Lamorte A, Tullio M, et al. Point-of-care multiorgan ultrasonography for the evaluation of undifferentiated hypotension in the emergency department. *Intensive Care Med* 2013; 39: 1290–1298.
21. Schmidt GA, Koenig SJ, Mayo PH. Shock: ultrasound to guide diagnosis and therapy. *Chest* 2012; 142:1042–1048.
22. Narasimhan M, Koenig SJ, Mayo PH. Advanced echocardiography for the intensivist: part I. *Chest* 2014; 145:129–134.
23. Narasimhan M, Koenig SJ, Mayo PH. Advanced echocardiography for the intensivist: part II. *Chest* 2014; 145:135–142.

24. Fox JC, Lahham S, Maldonado G, Klaus S, Aish B, Sylwanowicz LV. Hypertrophic cardiomyopathy in youth athletes: successful screening with point-of-care ultrasound by medical students. *J Ultrasound Med* 2017; 36:1109–1115.
25. Labovitz AJ, Noble VE, Bierig M, et al. Focused cardiac ultrasound in the emergent setting: a consensus statement of the American Society of Echocardiography and American College of Emergency Physicians. *J Am Soc Echocardiogr* 2010; 23:1225–1230.
26. Cholley BP. International expert statement on training standards for critical care ultrasonography. *Intensive Care Med* 2011; 37: 1077–1083.
27. Via G, Hussain A, Wells M, et al. International evidence-based recommendations for focused cardiac ultrasound. *J Am Soc Echocardiogr* 2014; 27:683.e1–683.e33.

Deep Vein Thrombosis

28. Kory PD, Pellecchia CM, Shiloh AL, Mayo PH, DiBello C, Koenig S. Accuracy of ultrasonography performed by critical care physicians for the diagnosis of DVT. *Chest* 2011; 139:538–542.
29. Birdwell BG, Raskob GE, Whitsett TL, et al. The clinical validity of normal compression ultrasonography in outpatients suspected of having deep venous thrombosis. *Ann Intern Med* 1998; 128:1–7.
30. Caggiati A, Bergan JJ, Gloviczki P, et al. Nomenclature of the veins of the lower limbs: an international interdisciplinary consensus statement. *J Vasc Surg* 2003; 36:416–422.
31. Hellinger JC. Venous anatomy of the lower extremities. In: Ho V, Reddy RP (eds). *Cardiovascular Imaging*. Philadelphia, PA; Elsevier Saunders 2011:1019–1029.
32. Fraser JD, Anderson DR. Deep venous thrombosis: recent advances and optimal investigation with ultrasound. *Radiology* 1999; 211:9–24
33. Narasimhan M, Koenig SJ, Mayo PH. A whole body approach to point of care ultrasound. *Chest* 2016; 150:772–776.
34. Pellerito JS, Polak JF. *Introduction to Vascular Ultrasonography*. New York, NY: Elsevier Health Sciences; 2012:353–376.
35. Minet C, Potton L, Bonadona A, et al. Venous thromboembolism in the ICU: main characteristics, diagnosis and thromboprophylaxis. *Crit Care* 2015; 19:287.
36. Lensing AW, Prandoni P, Brandjes D, et al. Detection of deep-vein thrombosis by real-time B-mode ultrasonography. *N Engl J Med* 1989; 320:342–345.
37. Cogo A, Lensing AW, Prandoni P, Hirsh J. Distribution of thrombosis in patients with symptomatic deep vein thrombosis: implications for simplifying the diagnostic process with compression ultrasound. *Arch Intern Med* 1993; 153:2777–2780.
38. Blaivas M. Ultrasound in the detection of venous thromboembolism. *Crit Care Med* 2007; 35(suppl):S224–S234.
39. Poppiti R, Papanicolaou G, Perese S, Weaver FA. Limited B-mode venous imaging versus complete color-flow duplex venous scanning for detection of proximal deep venous thrombosis. *J Vasc Surg* 1995; 22:553–557.
40. Wester JP, Holtkamp M, Linnebank ER, et al. Non-invasive detection of deep venous thrombosis: ultrasonography versus duplex scanning. *Eur J Vasc Surg* 1994; 8:357–361.
41. Crisp JG, Lovato LM, Jang TB. Compression ultrasonography of the lower extremity with portable vascular ultrasonography can accurately detect deep venous thrombosis in the emergency department. *Ann Emerg Med* 2010; 56:601–610.
42. Pomero F, Dentali F, Borretta V, et al. Accuracy of emergency physician–performed ultrasonography in the diagnosis of deep-vein thrombosis: a systematic review and meta-analysis. *Thromb Haemost* 2013; 109:137–145.
43. West JR, Shannon AW, Chilstrom ML. What is the accuracy of emergency physician–performed ultrasonography for deep venous thrombosis? *Ann Emerg Med* 2015; 65:699–701.
44. Tomkowski WZ, Davidson BL, Wisniewska J, et al. Accuracy of compression ultrasound in screening for deep venous thrombosis in acutely ill medical patients. *Thromb Haemost* 2007; 97:191–194.
45. Goldhaber SZ, Bounameaux H. Pulmonary embolism and deep vein thrombosis. *Lancet* 2012; 379:1835–1846.
46. Eichinger S, Heinze G, Jandeck LM, et al. Risk assessment of recurrence in patients with unprovoked deep vein thrombosis or pulmonary embolism: the Vienna model. *Circulation* 2010; 121: 1630–1636.
47. Snow V, Qaseem A, Barry P, et. Management of venous thromboembolism: a clinical practice guideline from the American College of Physicians and the American Academy of Family Physicians. *Ann Intern Med* 2007; 146:204–210.
48. Kearon C. Natural history of venous thromboembolism. *Circulation* 2003; 107:I-22–I-30.
49. American Institute of Ultrasound in Medicine. AIUM practice parameter for the performance of peripheral venous ultrasound examinations. American Institute of Ultrasound in Medicine website; 2015. https://www.aium.org/resources/guidelines/peripheralVenous.pdf.

Thoracic

50. Volpicelli G, Elbarbary M, Blaivas M, et al. International evidence-based recommendations for point-of-care lung ultrasound. *Intensive Care Med* 2012; 38:577–591.
51. Koenig SJ, Narasimhan M, Mayo PH. Thoracic ultrasonography for the pulmonary specialist. *Chest* 2011; 140:1332–1341.
52. Lichtenstein DA, Menu Y. A bedside ultrasound sign ruling out pneumothorax in the critically ill: lung sliding. *Chest* 1995; 108: 1345–1348.

53. Lichtenstein D, Mezière G, Biderman P, Gepner A. The "lung point": an ultrasound sign specific to pneumothorax. *Intensive Care Med* 2000; 26:1434–1440.
54. Lichtenstein D, Mezière G, Biderman P, Gepner A, Barré O. The comet-tail artifact: an ultrasound sign of alveolar-interstitial syndrome. *Am J Respir Crit Care Med* 1997; 156:1640–1646.
55. Copetti R, Soldati G, Copetti P. Chest sonography: a useful tool to differentiate acute cardiogenic pulmonary edema from acute respiratory distress syndrome. *Cardiovasc Ultrasound* 2008; 6:16.
56. Agricola E, Bove T, Oppizzi M, et al. "Ultrasound comet-tail images": a marker of pulmonary edema—a comparative study with wedge pressure and extravascular lung water. *Chest* 2005; 127:1690–1695.
57. Lichtenstein DA, Mezière GA, Lagoueyte JF, Biderman P, Goldstein I, Gepner A. A-lines and B-lines: lung ultrasound as a bedside tool for predicting pulmonary artery occlusion pressure in the critically ill. *Chest* 2009; 136:1014–1020.
58. Lichtenstein DA, Mezière GA. Relevance of lung ultrasound in the diagnosis of acute respiratory failure: the BLUE protocol. *Chest* 2008; 134:117–125.
59. Lichtenstein DA, Lascols N, Mezière G, Gepner A. Ultrasound diagnosis of alveolar consolidation in the critically ill. *Intensive Care Med* 2004; 30:276–281.
60. Zanobetti M, Poggioni C, Pini R. Can chest ultrasonography substitute standard chest radiography for evaluation of acute dyspnea in the emergency department? *Chest* 2011; 139: 1140–1147.
61. Balik M, Plasil P, Waldauf P, Pazout J, Fric M, Otahal M, Pachl J. Ultrasound estimation of volume of pleural fluid in mechanically ventilated patients. *Intensive Care Med* 2006; 32:318.
62. Remerand F, Dellamonica J, Mao Z, et al. Multiplane ultrasound approach to quantify pleural effusion at the bedside. *Intensive Care Med* 2010; 36:656–664.